



Research Paper

Chemical and Microplastic Induced Histological Changes in *Eetroplus Suratensis*

*Sheney Muraly & Jomon K.V.

(Department of Zoology, St.Berchmans Autonomous College, Changanacherry, Kottayam Kerala, India)

ABSTRACT :

This study investigated the histological effects of chemicals and microplastics in the most preferred indigenous fish, *Eetroplus suratensis* in the Vembanad lake Kerala, India. Samples were collected from the Vembanad lake for four months, from December 2019 to march2020. Study area is reported as highly polluted. The study demonstrated serious damages in the tissues investigated, like vacuole formations, loss of integration of cells, pyknotic nucleus etc. It also showed the presence of plastics in gills and intestinal tissues. Results indicated elevated levels of tissue damage in the sample collected during pre monsoon months compared to that of the post monsoon month. Study reflects that edible fishes are seriously affected in their natural habitat and emphasizes the need forthe conservation of such water bodies.

Keywords: *Eetroplus suratensis*, Microplastics, Histopathology.

Received 06 July, 2021; Revised: 18 July, 2021; Accepted 20 July, 2021 © The author(s) 2021.

Published with open access at www.questjournals.org

I. INTRODUCTION

Pollution of aquatic environmental is a global issue. Exposure to serious pollutants keeps the life of aquatic organisms especially fishes at a risk. Fishes play an inevitable role in the trophic food web and are the best indicators of pollution in aquatic environment.

Vembanad lake with Ramasar site no 1214 is a life supporting costal wetland in Kerala. Vembanad wetland, the largest estuary in the state of Kerala, lies between 09°00'-10° 40' N and 76° 00'-77°30' E. Municipal wastes, fuel leaking, plastic wastes and washing off of the fertilizers and pesticides from the agricultural lands polluted the water body[1].Back water tourism in the lake also resulted in large scale dumping of wastes into the lake [2].

Plastics accumulation in biological system is a growing concern. These plastics degrade as a result of physical aberrations and prolonged UV exposure as micro and macro particles. Such smaller plastic particles especially microplastics are more dangerous, as they are easily ingested by fishes and can enter organs and body fluids of organisms and thus propagate up the food chain.[3]. Presence of microplastic (<5mm) in Vembanad lake has already been demonstrated [4]. These particles remain in ecosystem and subsequently get ingested by organisms. Microplastic can pose ecological threats to flora and fauna [5,6]. Deterioration of habitats affects the quantity and quality of fauna and flora. There are signs of decline in the Vembanad fishery resources, evident in the lesser numbers of species and decline of fishery production [7]. Bioaccumulation of chemicals in fishes also affect human when they are taken as food [8]

The objectives of the study were to analyze and understand the effect of chemicals and microplastics in the body on fish, *Eetroplus suratensis*. *Eetroplus suratensis*, the branded pearl spot is the state fish of Kerala, largest among the indigenous cichlids native of Indian peninsula. Histopathological parameters were used for the evaluation of the health of fish.

II. METHODOLOGY

2.1 Study Area and Sampling

This study was conducted in the northern region of Vemband Lake. Study site is extremely a brackish water area, bordering the Ernakulum district of Kerala state. Sampling was carried out from three randomly selected sites [R1 R2 R3] with the help of local fisher man. Collections were done in two phases of the hydrological cycle, one in the month of December 2019 (post monsoon) and other in the months January to March 2020 (pre monsoon). Samples were transported to laboratory along with the water taken from the site in separate containers.

In laboratory the tissues such as muscle, liver and intestinal region were dissected out carefully for histological studies. From the monthly catch, one of largest fish from each site was selected and dissected for histological study. This procedure followed in each month. Histological slides prepared from sample fishes were compared with that of fishes bought from farm taken as control.

2.2 Histological Studies.

Histological studies were done by Hematoxylin-eosin staining. Dissected tissues- gills, muscle, intestine regions - were washed in buffered normal saline. The tissues were then fixed in Bouin's solution (prepared with saturated picric acid, formaldehyde, and acetic acid), for 48 hours and then dehydrated through graded alcohol series (70-100%), cleared in xylene and embedded in paraffin. Five mm thick paraffin sections were taken and stained with Haematoxylin-eosin. Histological preparations were photographed by stereo & light microscope at 10X eyepiece magnification and 40X objective magnification using Labomed (model vision 2000) with camera attachment. Sample images were analyzed by comparing with the standard.

III. RESULTS AND DISCUSSION

3.1(i) Histopathology of Gills

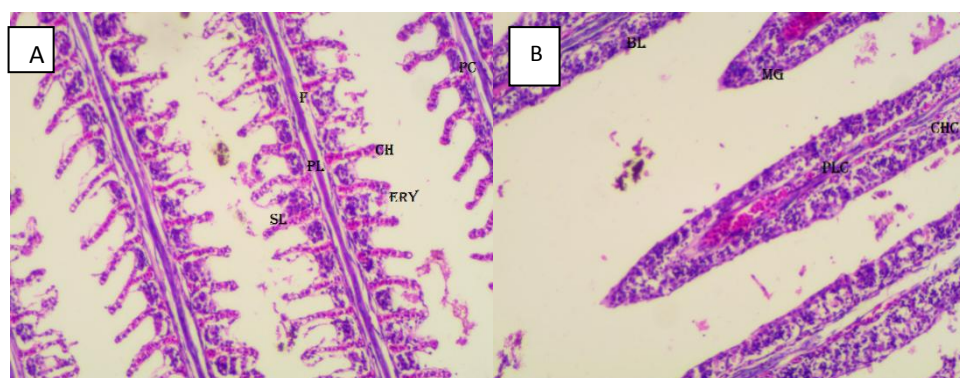

Plate 1; Fig. A & B. Histological comparison of gills in *E. suratensis*. Light micrographs of paraffin section stained with Hematoxylin and eosin (40x). Figure A showing the normal orientation of gills of control. Abbreviations used: (L)-Lamellae, (F)-Filament, (PL)-Primary lamellae, (SL)-Secondary lamellae, (ERY)-Nucleated Erythrocytes, (CH) Chloride cells and (PC)-Pillar cells. Figure B showing the alteration. (BL)- basal Layer, (MG)-Mucous glands, (PLC)- Pillar cells, (CHC)-Chloride cells. {Sample order: Control-(A), Test-December(B), January(C), February(D), March(E)}

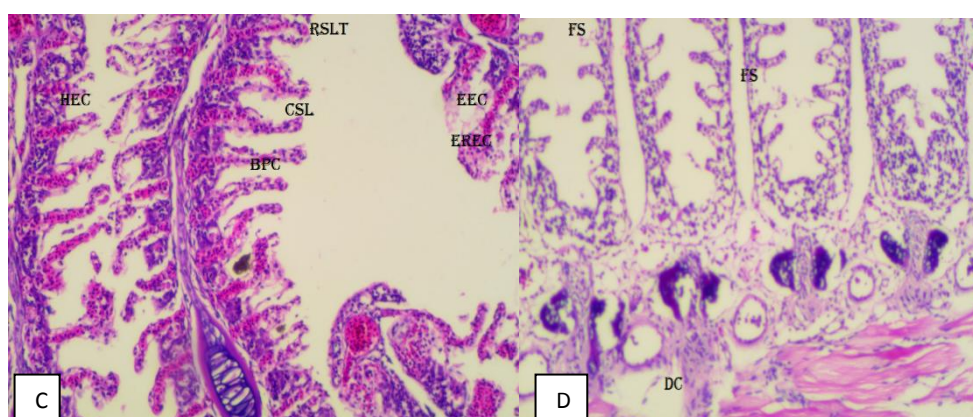


Plate 1; Fig. C & D. Histological changes of gills in *E. suratensis*. Light micrographs of paraffin section stained with Hematoxylin and eosin (40x) showing the gills. Abbreviations used: (LS)-Lamellar separation, (FS)- Filament separation, separation of the basement membrane, Curling of the lamellae. (DC)-disintegration of cells. Fig C shows the rupture of the secondary lamellae, Breakdown of pillar cells, oedema and rupture of epithelial cells, (VF)- Vacuolization.

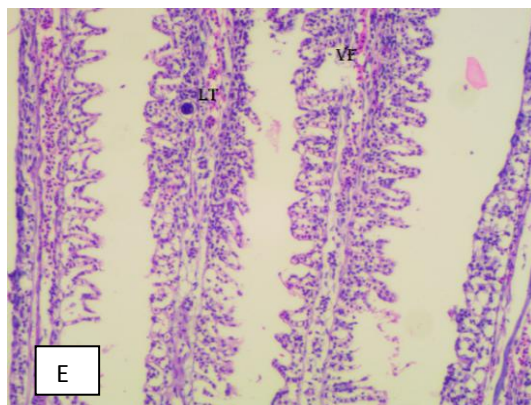


Plate 1:Fig.E, Histological changes of gills in *E.suratensis*. Light micrographs of paraffin section stained with Hematoxylin and eosin (40x) showing the gills. Abbreviations used:LT-Telangiectasis at lamellae, Degenerative changes, Vacuolated epithelium,(LF)-Lamellar fusion, (DF)-Damaged filament, (EREC)-oedema and rupture of epithelial cells,(EEC)-oedema of epithelial cells,(CSL)-curling of secondary lamellae,(RSLT)-rupture of secondary lamellae tip,(BPC)-breakdown of pillar system.

Plate 1, Fig A shows nature of gill of the control specimen. Gills are with four gill arches with two rows of secondary lamellae on the sides of primary lamellae consisting of centrally placed central axis also called filament, with chloride cells. The lamellae are lined by squamous epithelium they have pillar cells and chloride cells with well-marked inter lamellar spaces. (Plate 1, Fig A). The gill epithelium is thin with surface area allowing the higher exposure to water and thereby exchange of gases. Gills are also regulating the exchange of salt and water and have role in excretion of nitrogenous wastes. The primary lamellae covered with salt secreting chloride cells functioning in ionic transport and in detoxification. Salt secreting cells are found mostly at proximal parts of primary lamellae.

The plate 1, figure B, C, D are images of gill sections of fishes collected during January and February respectively. Gills show noticeable pathological alterations in architecture including telangiectasis which is lamellar capillary aneurism, curling of secondary lamellae, hyperplasia (hyperplasia refers to augmentation in the number of normal cells) of epithelial cells, edema of epithelial cells, damage and breakdown of pillar system, lamellar clubbing, rupture of epithelia were observed. Other observations are (LF)-Lamellar fusion,(DF)-Damaged filament.(EREC)-oedema and rupture of epithelial cells, (EEC)-oedema of epithelial cells, (CSL)-curling of secondary lamellae, (RSLT)-rupture of secondary lamellae tip, (BPC)-breakdown of pillar system (Fig E).

Previous histopathological investigations showed that gill was the primary target tissue affected by chemicals. Gills are generally considered good indicator of water quality[9], being models for studies of environmental impact [10], since the gills are the primary route for the entry of external agents. Several other studies have shown similar effects of chemicals on fish gills [11,12].Destructive changes in gill tissue, such as intraepithelial edema in the lamellae, thick coating of mucus covering the entire gill filaments and lamellae, serious erosion of secondary lamellae, thickening of lamellae, inflammation of epithelial cells, breakages in primary lamellae, degeneration of secondary lamellae, tissue necrosis, rupture of epithelium were noticed during exposure of sub lethal concentrations of chemicals by Rao et al.[13]. Rao et al [14] recorded uncontrolled regeneration of the primary lamellae and secondary lamellae, hypertrophy, hyperplasia, necrosis of the epithelial cells, epithelial lifting, etc., in the gill of fish exposed to the chemical profenofos.

3.1(ii) Histopathology of Muscles

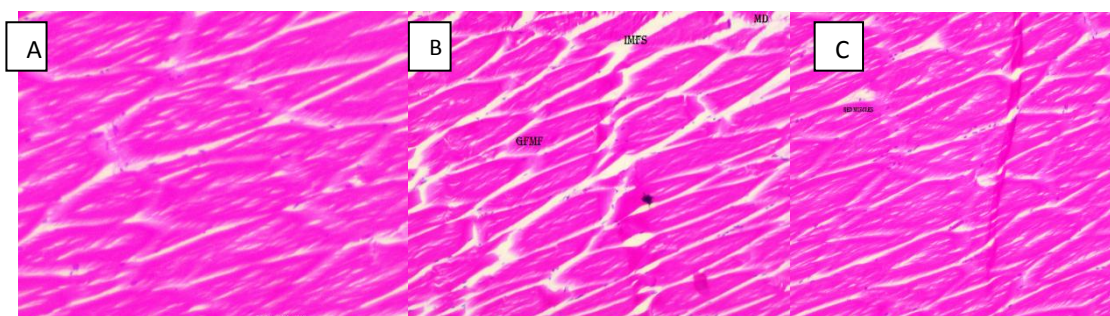


Plate 2; Fig.A&B&C, Histological comparison of muscles of *E.suratensis* . Stained with Hematoxylin and eosin (40x) control showing the normal orientation of Muscles in Fig A and altered orientation in B. Abbreviations used: D-degenerated muscle, increased gap formations in myofibrils.(GFMF)-gap formation in myofibril,(IMFS)-intermyofibrillar space,(MD)-muscle degradation.




Plate 2; Fig.D&E, Histological changes of muscles-*E.suratensis* .Section stained with Hematoxylin and eosin (40x) showing the of muscles. Abbreviations used:GFMP-Gap formation in myofibrils,DMF-Disintegrated myofibril,IMFS-intermyofibrillar space, EMF-oedema between muscle fibre and interstitial materials, (SMB)-shortening of muscle bundles,(DC)-dystrophic changes,V(MF)- vacuolated muscle fibers.

Muscle tissue prepared from control (Plate 2, Fig. A) consists of elongated muscle fibers held by connective tissues. They are divided into myotomes and each myofibril is composed of two types of myofilaments arranged giving striations the transverse bandings.

Fig.C & D & E shows edema, splitting of muscle fibers vacuolar formation with increase in inter spacing and separation of muscle bundles are seen in the histological analysis. Inter myofibrillar space is increased with necrosis and atrophy. Splitting of muscle fibers and vacuolar degeneration in muscle bundles were considered to be significant histopathological changes. The histopathological alterations observed in the present study were in agreement with those observed by many investigators who have studied the effects of different chemicals on fish muscles [15,16, 17].

3.1 (iii) Histopathology of Liver

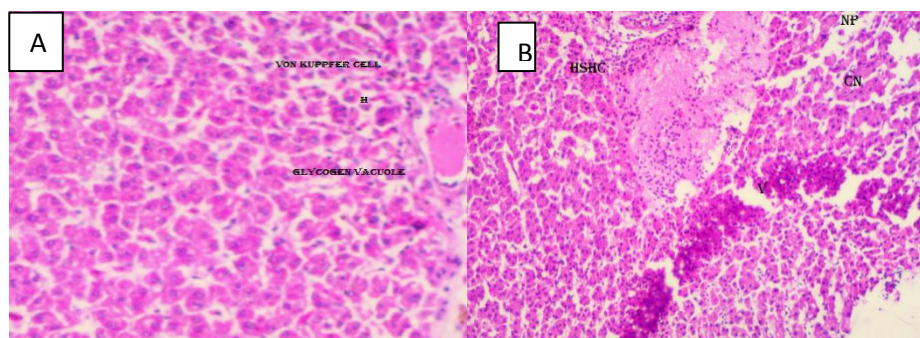


Plate 3; Fig.A&B: Histological changes in the liver tissue of *E.suratensis*. Section stained with Hematoxylin and eosin (40x) control showing the normal orientation of Liver in Fig A. Abbreviations used: H- hepatic cells, von kuppfer cells, Glycogen vacuoles, CD- Cytoplasmic degeneration, N –cellular necrosis, HSHC –Hydropic swelling of hepatocytes, CN cellular necrosis, NP -pyknotic nucleus.

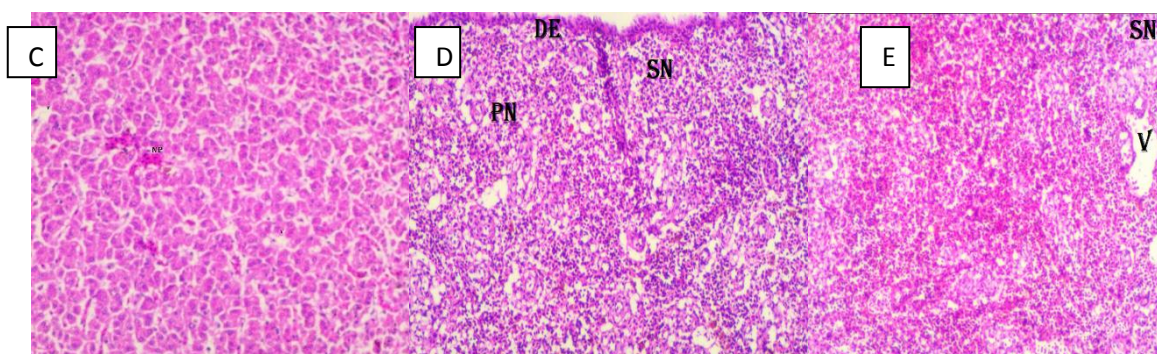


Plate 3; Fig.C&D&E: Histological changes of liver-*E.suratensis*. Stained with Hematoxylin and eosin (40x) showing the Liver. Abbreviations used: BC- blood congestion, vacuolisation, damaged epithelium (DE), (SN)- severe necrosis, Vacuoles (V), (PN)-pyknotic nucleus.

In the control the liver is reddish brown in Color. Serosus membrane covers the liver, the cells are hepatocytes which are round, circular nucleus blood sinusoids are also seen. It is composed of branching and anastomosing, two cell thick laminae or chords of hepatocytes. (Plate 3, Fig. A)

Major observations in Plate 3, Fig.C&D&E were detachment of cells, accumulation of dark granules, formation of cytoplasmic vacuoles, Pyknotic nucleus. Cytoplasm of hepatocytes became vacuolated. Histological changes in the liver could be attributed to the fact that, the liver is the major site of detoxification. It is expected that any toxicant or pollutant would reach there in abundance for detoxification and disposal and hence give earlier damage. The appearance of Pyknotic nuclei indicated that the cells became hypo functional. Hyperplasia, vacuolation, disintegrated blood vessels, disrupted hepatocytes, focal coagulative necrosis, disorganized hepatic canaliculi were observed by Sarkar et al.[18] in *Labeo rohita* exposed to cypermethrin.

3.1(iv) Histopathology of Intestine

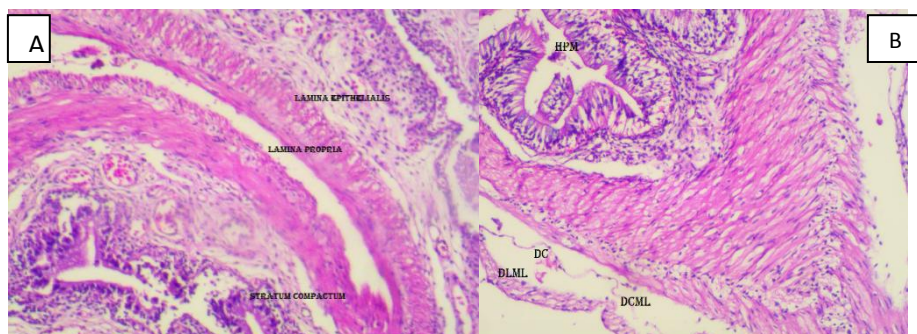


Plate 4; Fig.A&B: Histological comparison of the intestinal tissue of *E.suratensis*. Stained with Hematoxylin and eosin (40x) control showing the normal orientation of Intestine in control Fig A and alteration in B. Abbreviations used:(HPM)hyperplasia of mucosa,(DC)distended lumen,loss of orientation of cell and structure, (DLML)-damaged longitudinal muscle layer,(DCML)-damaged circular muscle layer

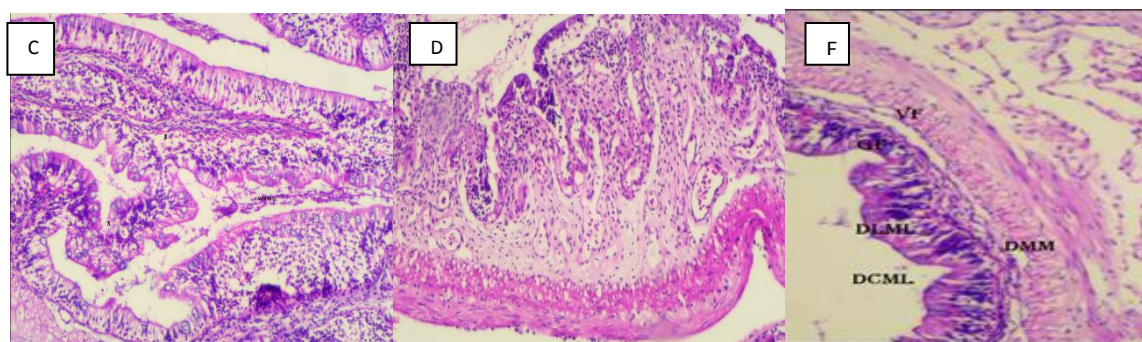


Plate 4; Fig.C&D&E Histological changes in the intestinal tissue of *E.suratensis*. Section stained with Hematoxylin and eosin (40x) showing the Intestine. Abbreviations used:flattened villi,swelling and damaged longitudinal muscles cellular necrosis,pyknotic nucleus,disarrangement of muscularis mucosa,cracked appearance of tissues, (DL)- distended lumen ,(DMM)- disarrangement of muscularis mucosa, (VF)- vacuole formations.

Plate 3, Fig A shows nature of intestinal tissue of the control specimen. The fundamental organization of the intestinal wall contains tunica mucosa with lamina propria it's a connective tissue inner circular and outer longitudinal muscles (tunica submucosa, tunica muscularis) intestinal mucous secreting cells are called goblet cells are seen in columnar cells. The anterior part functions in transportation of food from stomach, next part in the completion of digestion by enzyme secretion from accessory glands and to absorb the final products into the blood and lymph. (Plate 3; Fig.A)

The histological analysis of intestinal wall showed vacuole and lumen formations, sloughing off tissues hypertrophy of epithelial cells and excessive hypertrophy in villi caused fusion in them. Large areas of intestinal mucosa are found with damages, wreckage of secondary mucosal folds. Swollen longitudinal cells and Pyknotic nucleus. (Plate 4, Fig.B,C) (HPM) hyperplasia of mucosa , (DC)distended lumen(D&E).

The present results are in agreement with those observed by many investigators about the effects of different pesticides on fish intestine such as hexachlorocyclohexane [19](Das and Mukherjee, 2000); cyphenothrin [20] (Erkmen et al., 2000); [21] deltamethrin (Yildirim et al., 2006) and aldrin and heptachlor [22] (Campagna et al, 2007). Results also indicated elevated levels of tissue damage in the sample collected from pre monsoon seasons compared to that of post monsoon seasons.

3.2 Presence Of Microplastics:

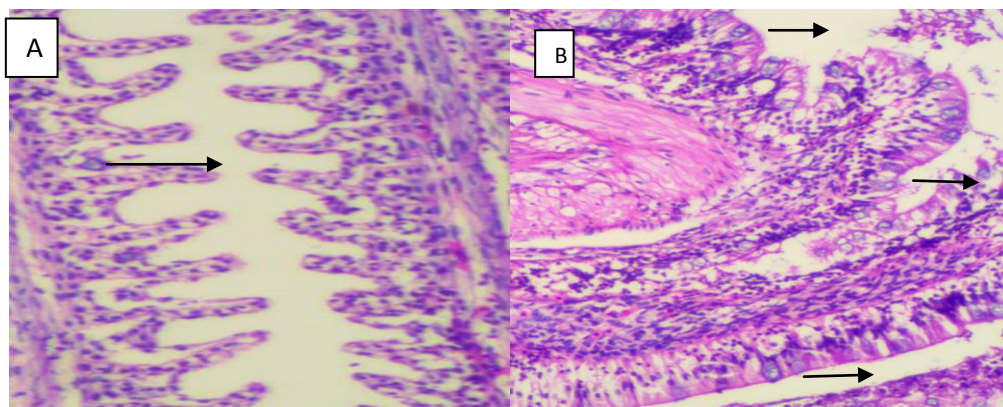


Plate 5, Fig A & B: A showing the Gills and B showing the Intestine, Presence of plastics at the gill surface.

The histological studies showed the presence of plastics in the gills and the intestinal areas (Plate 5, Fig A & B). The micro and macro plastics present in the water is taken by the fish during its meal and get lodged in the gills and intestine and other body parts which are in turn passed on to the next trophic level leading to bio magnification and higher accumulation of a pollutant in higher organisms. In fish, microplastics found to have caused adverse effects like intestinal alterations, oxidative stress, endocrine disruption, decreased predatory performance, hepatic stress etc. [23]. Trophic transfer and individual impact of nano-sized polystyrene in different species of freshwater food chain have been demonstrated [24]

IV. CONCLUSION

By anthropogenic actions and natural methods chemical from industries and agriculture land are washed into the Vembanadlake. These chemicals can cause serious damage to various tissues of fishes and its biomagnifications. It ultimately affects health of fish and their survival. Studies in Vembanad lake showed the drastic fall in (Catch Per Unit Effort) C.P.U. E from 21.05 to 13.78 kg/day for scare line fishing during 2002 to 2005 indicates the alarming trend of decline of pearl spots in the lake [25]. Pollution might be a parameter leading to the decline in population of fishes. Further these chemical will reach human through the edible fish and can affect human health. Careful measures shall be taken to reduce the pollution of aquatic body and to maintain the healthy population of aquatic organisms, especially fishes.

ACKNOWLEDGEMENT

I express my deep sense of gratitude to Kerala State Council For Science Technology & Environment, KSCSTE Thiruvananthapuram for funding my project.

REFERENCES

- [1]. Sruthy Sajeew, Selvam Sekar, Binoj Kumar, Venkatramanan Senapathi, Sang Yong Chung, Gnanachandrasamy Gopalakrishnan(2020). Variations of water quality deterioration based on GIS techniques in surface and groundwater resources in and around Vembanad Lake, Kerala, India. *Geochemistry*, Volume 80, Issue 4.
- [2]. Vincy M.V; Brilliant Rajan; and Pradeep Kumar A. P.(2012). Water Quality Assessment of a Tropical Wetland Ecosystem with Special Reference to Backwater Tourism, Kerala, South India. *International Research Journal of Environment Sciences*, Vol. 1(5), 62-68
- [3]. Hugo Jacob, Marc Besson, Peter W. Swarzenski, David Lecchini, and Marc Metian (2020). Effects of Virgin Micro- and Nanoplastics on Fish. *Trends, Meta-Analysis, and Perspectives.*, *Environmental Science & Technology* 54 (8), 4733-4745.
- [4]. Sruthy S, E.V. Ramasamy (2017) Microplastic pollution in Vembanad Lake, Kerala, India: The first report of microplastics in lake and estuarine sediments in India. *Environmental pollution*, 315-317.
- [5]. Rivard C, L Moens, K Roberts, J Brigham (1995). Starch esters as biodegradable plastics: Effects of ester group chain length and degree of substitution on anaerobic biodegradation. *Enzyme and Microb. technol*, 17, 848-852
- [6]. Shimao, M., (2001). Biodegradation of plastics. *Curr. Opin. Biotech.* 12
- [7]. Asha, C.V., Suson, P.S., Retina, C.I., Nandan, S.B., (2014). Decline in diversity and production of exploited fishery resources in vembanad wetland system: Strategies for better management and conservation. *Open. J. Mar. Sci.* 4, 344-357. DOI: 10.4236/ojms.2014.44031
- [8]. Fatima, S., Muzammal, M., Rehman, A., Rustam, S.A., Shehzadi, Z., Mehmood, A. and Waqar, M. (2020). Water pollution on heavy metals and its effects on fishes. *International Journal of Fisheries and Aquatic Studies*, 8(3): 6-14.
- [9]. Rankin, J. C.; Atagg, R. M.; Bolis, L. (1982), Effects of pollutants on gills. In-Gills, eds. D. F. Houlihan, J. C. Rankin, T. J., Shuttleworth. Cambridge University Press, New York, pp. 207-220.
- [10]. Wenderlaar Bonga, S. E.; Lock, A. A. C. (1992), Toxicants and osmoregulation in fish. *Neth. J. Zool.*, 42, 478-493

- [11]. Cengiz, E. I.; Unlu, E. (2003), Histopathology of gills in mosquitofish, *Gambusia affinis* after long-term exposure to sublethal concentrations of malathion. *J. Environ. Sci. Heal. B*, 38, 581-589
- [12]. Cengiz, E. I.; Unlu, E. (2006), Sublethal effects of commercial deltamethrin on the structure of the gill, liver and gut tissues of mosquitofish, *Gambusia affinis*: A microscopic study. *Environ. Toxicol. Phar.*, 21, 246-253.
- [13]. Rao, J. V.; Begum, G.; Sridhar, V.; Reddy, N. C. (2005), Sublethal effects of monocrotophos on locomotor behavior and gill architecture of the mosquito fish, *Gambusia affinis*. *J. Environ. Sci. Heal. B*, 40, 813-825.
- [14]. Rao, J. V.; Begum, G.; Jakka, N. M.; Srikanth, K.; Rao, R. N. (2006), Sublethal effects of profenofos on locomotor behavior and gill architecture of the mosquito fish, *Gambusia affinis*. *Drug. Chem. Toxicol.*, 29, 255-267.
- [15]. Nour, A. and Amer, A. (1995). Impairment of muscle performance in the Nile catfish *Clarias lazera* in response to hostathion insecticide contamination and/or gamma irradiation. *Journal of Egyptian German Society of Zoology*, 18,153 - 175.
- [16]. Das, B. and Mukherjee, S. (2000). A histopathological study of carp (*Labeo rohita*) exposed to hexachlorocyclohexane. *Veterinary Archives*, 70, 169 - 180.
- [17]. Mohamed, F.A.S. (2009). Histopathological studies on *Tilapia zilli* and *Solea vulgaris* from Lake Qarun, Egypt. *WorldJournal of Fish and Marine Science.*, 1, 29 - 39 (2009).
- [18]. Sarkar, B.; Chatterjee, A.; Adhikari, S.; Ayyappan, S. (2005), Carbofuran and cypermethrin induced histopathological alterations in the liver of *Labeo rohita* (Hamilton) and its recovery. *J. Appl. Ichthyol.*, 21, 131-135
- [19]. Das, B. and Mukherjee, S. (2000). A histopathological study of carp (*Labeo rohita*) exposed to hexachlorocyclohexane. *Vet. Arhiv*,70(4), pp. 169-180.
- [20]. Erkmén, B, Caliskan, M. and Yerli, S. (2000). Histopathological effects of cyphenothrin on the gills of *Lebistes reticulatus*. *Vet. Hum.Toxicol.*, 42(1), pp. 5-7.
- [21]. Yildirim, M. Benli, A. Selvi, M. Ozkul, A. Erkoç, F. and Kocak, O. (2006). Acute toxicity, behavioral changes and histopathological effects of deltamethrin on tissues (gills, liver, brain, spleen, kidney, muscle, skin) of Nile tilapia (*O. niloticus* L.) fingerlings. *Environ.Toxicol*, 21(6), pp. 614-620.
- [22]. Campagna, A. Eler, M. Fracacio, R.J. Rodrigues, B. and Verani, N. (2007). The toxic potential of aldrin and heptachlor on *Danio rerio* juveniles (Cypriniformes, Cyprinidae). *Ecotoxicol.*, 16(3), pp. 289-298.
- [23]. Anderson, D., Yu, T. W., Phillips, B., & Schezer, P. (1994). The effect of various antioxidants and other modifying agents on oxygen radical-generated DNA damage in human lymphocytes in the comet assay. *Mutation Research*, 307,261–271.
- [24]. Yooeun Chae, Dokyung Kim, Shin Woong Kim & Youn-Joo An, Trophic transfer and individual impact of nano-sized polystyrene in a four-species freshwater food chain, *Scientific REPOrTS* ,(2018) 8:284 ,DOI:10.1038/s41598-017-18849-y.
- [25]. Unnithan, V.K., S.Bijay Nandan and C.K. Vava. 2001. Ecology and Fisheries Investigation in Vembanad lake. *Bull.No.107. Central Inland Capture Fisheries research Institute, Barrackpore, W.Bengal.* 38pp