



## Herbal Remedies In The Treatment Of Glioblastoma A Case Report

Ivo Trogrlić<sup>1</sup>, Dragan Trogrlić<sup>1</sup>, Zoran Trogrlić<sup>1</sup>

*Family business "DREN" Ltd, Žepče, Bosnia & Herzegovina*

**Corresponding author: Dragan Trogrlić**

Phone/Fax: 387 (0) 32 881-774

Received 02 September, 2014; Accepted 15 September, 2014 © The author(s) 2014. Published with open access at [www.questjournals.org](http://www.questjournals.org)

**ABSTRACT:-** This article reports the case of a 15-year old girl suffering from glioblastoma multiforme (GBM) that developed on the grounds of previously uncovered diffuse (grad 2) astrocytoma. MRI revealed the presence of an expansive formation measuring 70x60x50 mm in size. The patient was in a bad shape. Oncologic GBM treatment boiled down to two consecutive surgeries followed by standard radio-and chemotherapy initiated a month after the second surgery. The chemotherapy in question made use of temozolomide withdrawn after 28 days. As for phytotherapy, it was introduced shortly after the second surgery and was taken for 18 consecutive months, following which the phytotherapy had been gradually put down to the cessation point. A control MRI completed after the oncologic therapy and phytotherapy launch, revealed the presence of a tumour residuum that continued to reshape and shrink with each and every consecutive MRI control. A control MRI completed at month 30 post phytotherapy, revealed a complete tumour regression with no signs of recurrence at all. Given the baseline tumour dimensions, the oedema that affected almost the entire left hemisphere, the presence of necrosis, a far too short oncologic treatment and the bad shape the patient was found in prior to surgery, we have grounds to believe that GBM regression and 4-year long recurrence-free survival would not be possible without the aid of phytotherapy.

**KEYWORDS:-** glioblastoma multiforme, phytotherapy, brain oedema

### I. INTRODUCTION

Glioblastoma ( GBM ) is a malignant tumour of an astrocytic origin. According to the classification proposed by the World Health Organisation (WHO), its level of differentiation is considered to be 4 ( Louis et al, 2007 ). It is the most common brain tumour accounting for 15-17% of all intracranial tumours, while its share in glial tumours amounts to 60-75% ( Castro et al, 2003). GBM is one of the most ominous tumours encountered in humans. Less than 20% of the diseased get to live a year, and only 3% as long as three years post diagnosing ( Ohgaki and Kleihues, 2005 ). Such a tumour can arise on two molecularly and genetically different grounds, dependent on which mutually different age groups shall be affected (Burger and Scheithauer, 2007 ). In almost 90% of cases, GBM develops in form of a primary, *de novo* tumour, and mostly affects the elderly. The remaining 10% are secondary GBMs that originate from better-differentiated astroglial tumours and are predominantly encountered in younger people and even children (Van Meir et al, 2010 ). The average survival period of those diagnosed with a secondary GBM comes down to 7.8 months, while patients diagnosed with a primary GBM get to live 4.7 months on the average. According to the common belief, longer survival periods seen in secondary GBM cases can most probably be attributed to younger age of the affected patients (Ohgaki et al, 2004 ). Oncologic treatment that allows for a bit longer survival period, encompasses neurosurgery followed by combined radio-and chemotherapy and terminated after 5-6 additional chemo cycles ( Stupp et al, 2005 ).

This article brings a case suggesting that phytotherapy might be an effective mean of GBM growth control and quality-of-life (QoL) improvement. It aims at presenting the possibility of prolonging the life of GBM patients by virtue of pharmacologically active ingredients which are to be found in phytotherapeutic mixtures.

## II. CASE REPORT

The article brings a case of a 15-year old girl from B&H, diagnosed with a lower-grade astrocytoma in the year 2005, which eventually transformed into a secondary glioblastoma multiforme (GBM) as suggested by the tumour site, p53 protein activity, age of the diseased and the time span within which the transformation of the baseline tumour was witnessed (Ohgaki et al, 1999 ). The first neurosurgery was completed in Ljubljana (Slovenia) in November 2005 due to grade 2 astrocytoma. The second neurosurgery took place on the premises of the INI Institute Hannover (Germany) in August 2008. Following the second surgery, brain MRI controls and evaluations have been scheduled on a regular basis. The MRI completed on 12/17/2009 and urged by fairly frequent seizures, revealed the presence of a lesion situated adjacent to the tentorium, evoking a profound suspicion on the recurrence of the primary disease. In the subsequent course, regular monitoring and wait-and-see strategy were recommended (so that no therapy was launched).

Soon after, health deterioration had been witnessed. The patient was sleepy and had hard time focusing. Between February and March 2010, two sudden fainting episodes were seen, due to which a control MRI was urgently scheduled for 03/26/2010. The latter revealed the presence of a major glial tumour recurrence, measuring 70x60x50 mm in size (Figure 1).

Arrangements were made to transfer the girl from B&H to Zagreb (Croatia) on 04/06/2010 in order to continue treatment. However, in the interim period a sudden deterioration of her state of consciousness was witnessed; she went into a coma caused by the spontaneous bleeding from the brain tumour, so that on 04/01/2010 an urgent surgery in terms of left-sided parietal/temporal/occipital decompressive craniotomy, haematoma evacuation and expansive process reduction had to be performed in Tuzla (B&H). Given the fact that a postoperative brain CT revealed the persistence of a brain oedema and the expansive process, the girl was subjected to a decompressive re-craniotomy and additional expansive process resection. Following the reoperation in reference, the second control CT was completed, yielding satisfactory results, so that the girl was waken up on 04/05/2010 and ceased to be ventilated mechanically. Under the circumstances, the pre-planned transfer to Zagreb took place on 04/12/2010.

On 04/14/2010, a surgery in terms of maximal tumour mass reduction was undertaken. The sampled tumour tissue was analysed both during and post surgery. The analysis revealed the tumour to be of a highly anaplastic glial kind, to be featured by a pronounced vascular proliferation, and to harbour major foci of haemorrhagic necrosis. Within the tumour, a vivid mitotic activity was seen. Adjacent to the necrotic areas' margins, a bulk of foamy macrophages and haemosiderophages, as well as gliosis were found. As for immunocytochemistry, 20% of the tumour cells were p53-positive. The final diagnosis read as follows: glioblastoma multiforme (GBM). On 04/22/2010 the patient was transferred back to Tuzla (B&H) in order to continue treatment.

Immediately after being transferred to Zagreb, the patient started to take herbal remedies. In the first four phytotherapy months she had been treated with 6 types of herbal preparations, following which the latter were reduced to 5. The preparations differed in their composition, but were all made solely of remedial plants pounded to the standard degree (Lukić, 1993). The preparations were unanimously taken in form of tea, each serving thereby being prepared using 1.5 g of the herbal mixture and 200 cm<sup>3</sup> of water. Each herbal remedy was taken once a day in the regular time intervals, starting from 6 am to 10 pm (during the time when 6 herbal teas were in use) and later on, when the number of remedial teas was reduced to 5, from 7 am to 9 pm.

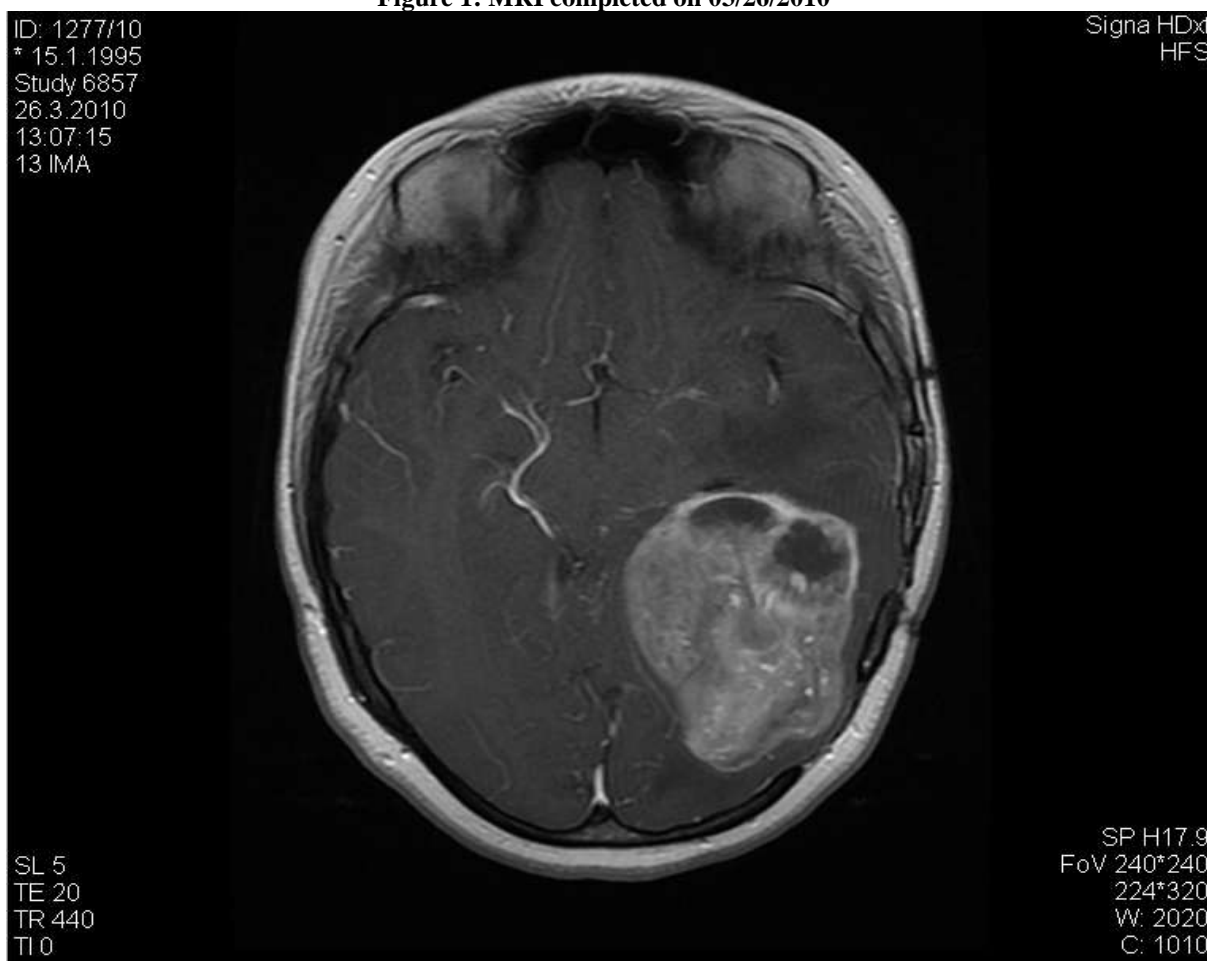
Of note, herbal remedies used to treat glioblastoma differ in their contents from those used for macroprolactinoma treatment. The outcomes of macroprolactinoma phytotherapy were published in 2012 ( Trogrlić et al, 2012 ).

From 05/17/2010 to 06/23/2010 the girl had been treated on the premises of the Radiology Department, where conformal brain tumour (GBM) radiotherapy targeted at the left occipital/parietal/temporal region had been carried out using a linear accelerator having a power of 6 MW. The total applied dose equalled to 56 Gy, and was divided into 28 fractions. The concurrent chemotherapy made use of temozolomide capsules administered in the dose of 75 mg/m<sup>2</sup> body surface. Nausea and occasional vomiting that arose on the grounds of the administered therapy were managed using antiemetic drugs. The patient was eventually released from hospital in a good overall health. Throughout the course of radio-and temozolomide chemotherapy, she had never ceased to take herbal remedies as well. Following the completion of the above therapy, no further oncologic treatment was attempted, but the patient continued to take phytotherapeutic mixtures. As mentioned before, from September 2010 on, the number of herbal remedies was reduced to 5, taken regularly once a day for the next 14 months. Due to the continuous regression of the tumour residuum seen on the control MRIs completed on 12/23/2010 (Figure 3), 05/17/2011 and 09/20/2011, the phytotherapy was further reduced. For the sake of clarity and case report precision, the presence of the above tumour residuum was first established on 09/20/2010 (Figure 2). The number of the employed herbal remedies remained the same, but the remedies were now taken not every, but every other day. Based on the outcome of the control MRI completed on 03/09/2012 that revealed the absence the tumour recurrence and the steadiness of the tumour residuum dimensions as

compared to the MRI completed on 09/20/2011, the phytotherapy was further reduced to 5 herbal preparations taken every third day. Following the completion of the control MRI scheduled for 09/19/2012 (Figure 4) that revealed the progression-free status with the tumour residuum being virtually undetectable, the girl completed another 3-month phytotherapy cycle, throughout which 5 herbal remedies had been taken every third day and after which the phytotherapy was put to a stop after being taken 33 months in a row. The controlled MRI scannings from 02/25/2013, 09/18/2013 and 03/11/2014 (Figure 5) has confirmed once more that there is no disease progression. These scannings have been done after the completed FT.

## II. MRI CHRONOLOGY

Figure 1: MRI completed on 03/26/2010



After the sudden deterioration of the patient's health seen within February 2010 – March 2010 timeframe, an urgent MRI was completed, revealing the presence of a major glial tumour recurrence featured by the signs of necrosis, cystic degeneration and peri-focal oedema. The supra-tentorial dimensions of the tumour equalled to 70x60x50 mm and the infra-tentorial ones to 30x20x15 mm.

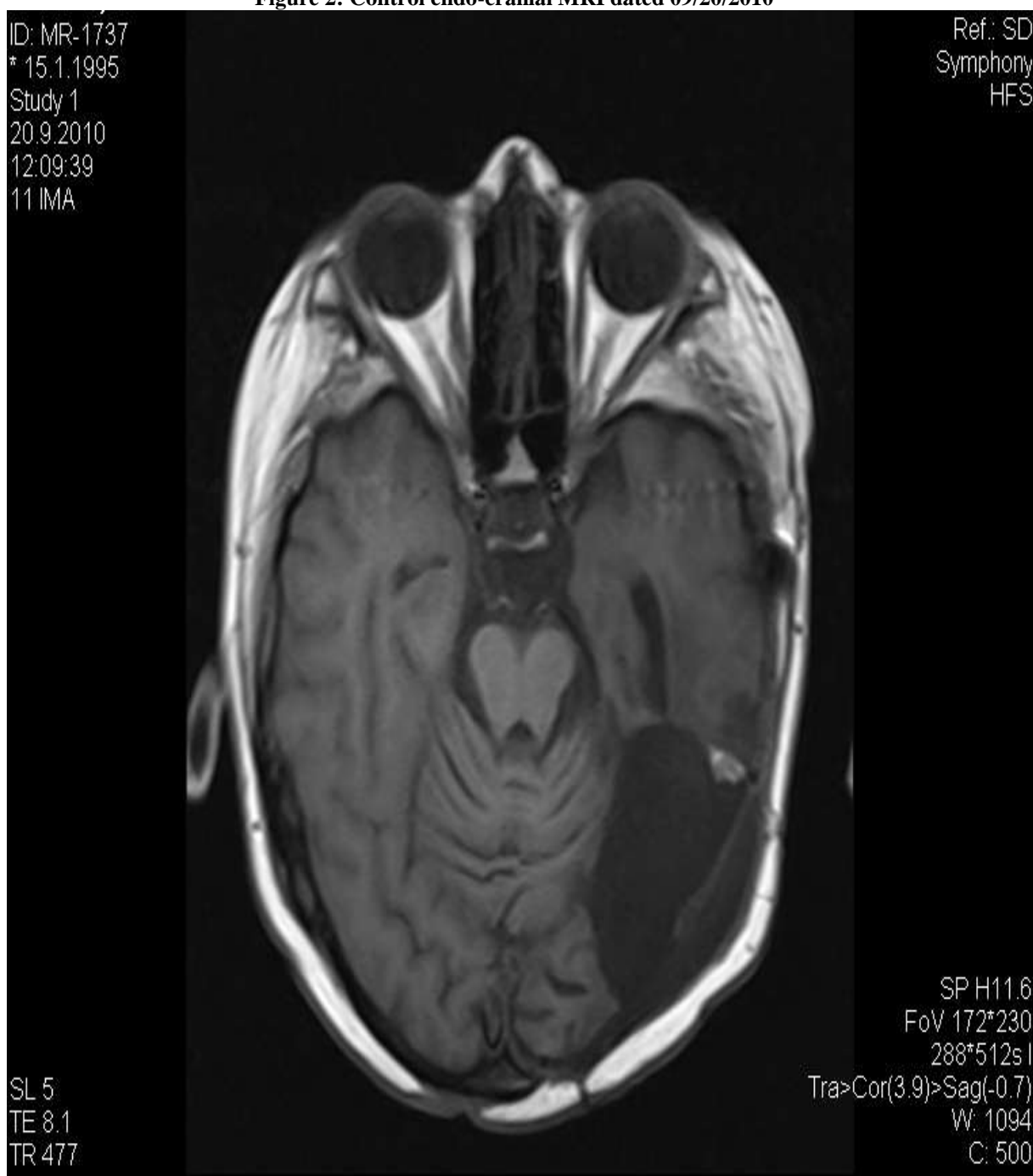
Below please find the excerpt from the Letter of Discharge dated 03/26/2010. Like with all other excerpts that follow, this one also represents an exact quotation/strict translation of the pertaining medical records, and reads as follows:

“State post left-sided sub-occipital and temporal osteoplastic craniotomy.

The left temporal/occipital/parietal region is occupied by a large expansive formation featured by the signs of necrosis, cystic degeneration, intense non-homogeneous CSF flow enhancement, restricted diffusion arising on the grounds of haemosiderin depositions, and peri-focal oedema.

To the left, the tumour propagates through the tentorium and exerts compression upon the left cerebellar hemisphere, the vermis, the 4<sup>th</sup> brain chamber and the cerebellar pons. Oedema can mostly be found in the temporal/occipital, but partly also in the parietal region, and encompasses the splenium of the callous body as well. The oedema also affects almost the entire left cerebral hemisphere”.

Figure 2: Control endo-cranial MRI dated 09/20/2010

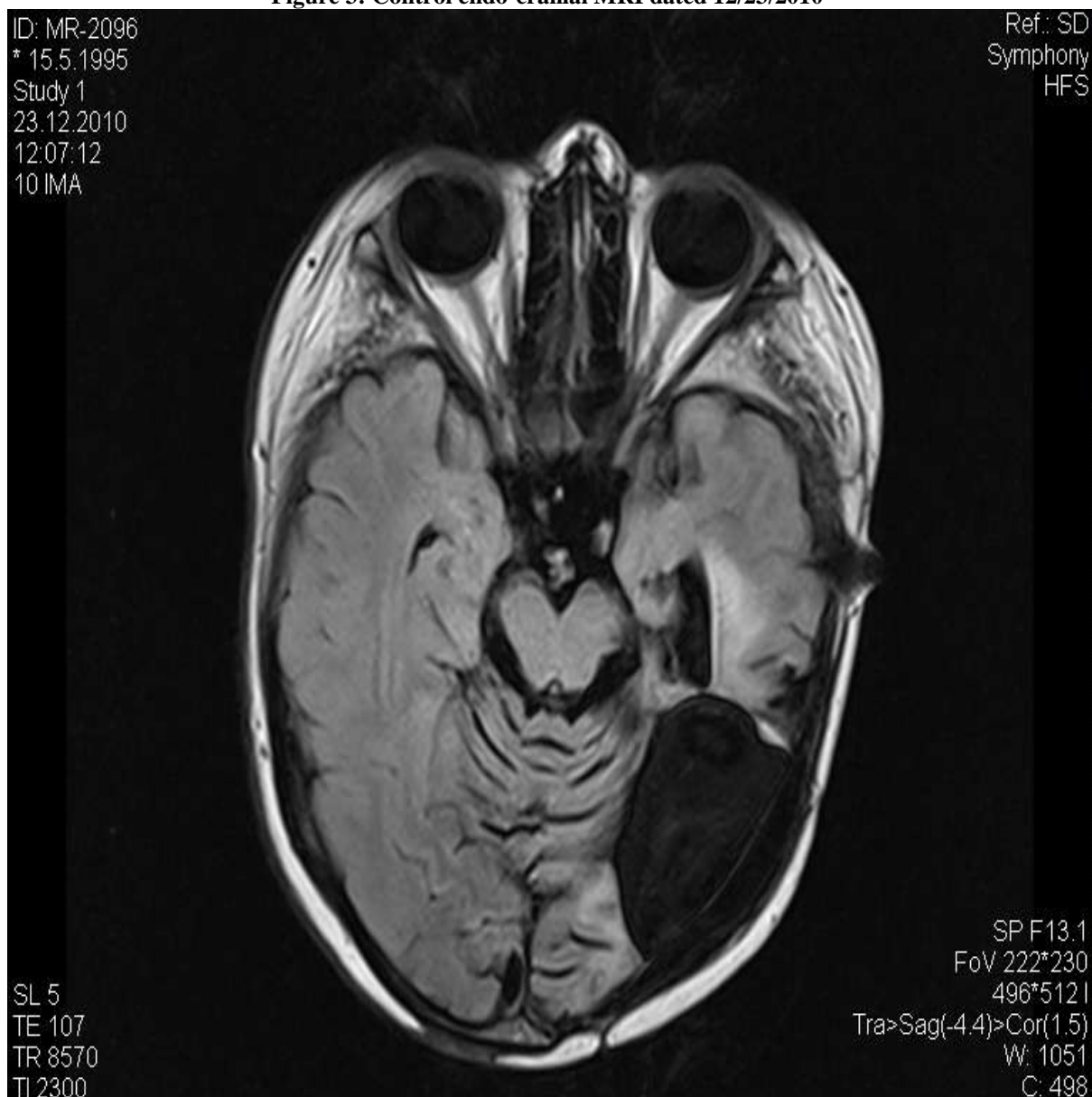


**“State post left-sided osteoplastic craniotomy.** In the temporal/parietal/occipital region, as well as in the region occupied by the lateral and medial/occipital/temporal gyri and hippocampus (whose body and tail had been partly resected), the zone following the CSF flow footsteps is evidenced, measuring not more than 59x36x33 mm (AP-CC-LL) on this day. The zone in reference corresponds to postoperative encephalomalacic zone in whose anterior/lateral portion an iso-signalling T2W lesion can be documented, having the maximal dimensions of 8x6 mm.

**Resume:**

1. State post left-sided temporal/occipital/parietal osteoplastic craniotomy, featured by the signs of postoperative malacia of the brain parenchyma in whose anterior/lateral aspect a tumour residuum measuring 8x6mm in size can be evidenced.
2. Sub-dural hygroma, found in the surgery zone.
3. Inflammatory changes of the left mastoid cells.”

Figure 3: Control endo-cranial MRI dated 12/23/2010



**“State post left-sided osteoplastic craniotomy.** In the temporal/parietal/occipital region, in specific in the area occupied by the lateral and medial/occipital/temporal gyri and the hippocampus (whose body and tail had been partly resected), a zone following the CSF flow footsteps can be found, measuring not more than 53x41x31 mm on this day and corresponding to a postoperative encephalomalacic zone whose anterior/lateral portion harbours a T1W/ T2W, currently hyper-signalling lesion; photo-stimulation failed to evoke any signal attenuations or extinctions. No PKPs have been seen. The maximal dimensions of the lesion in reference are 3x6x8 mm (AP-CC-LL).

**Resume:**

1. State post left-sided temporal/occipital/parietal osteoplastic craniotomy, featured by the signs of postoperative malacia of the brain parenchyma whose anterior/lateral portion accommodates the zone measuring 3x6x8 mm in size.

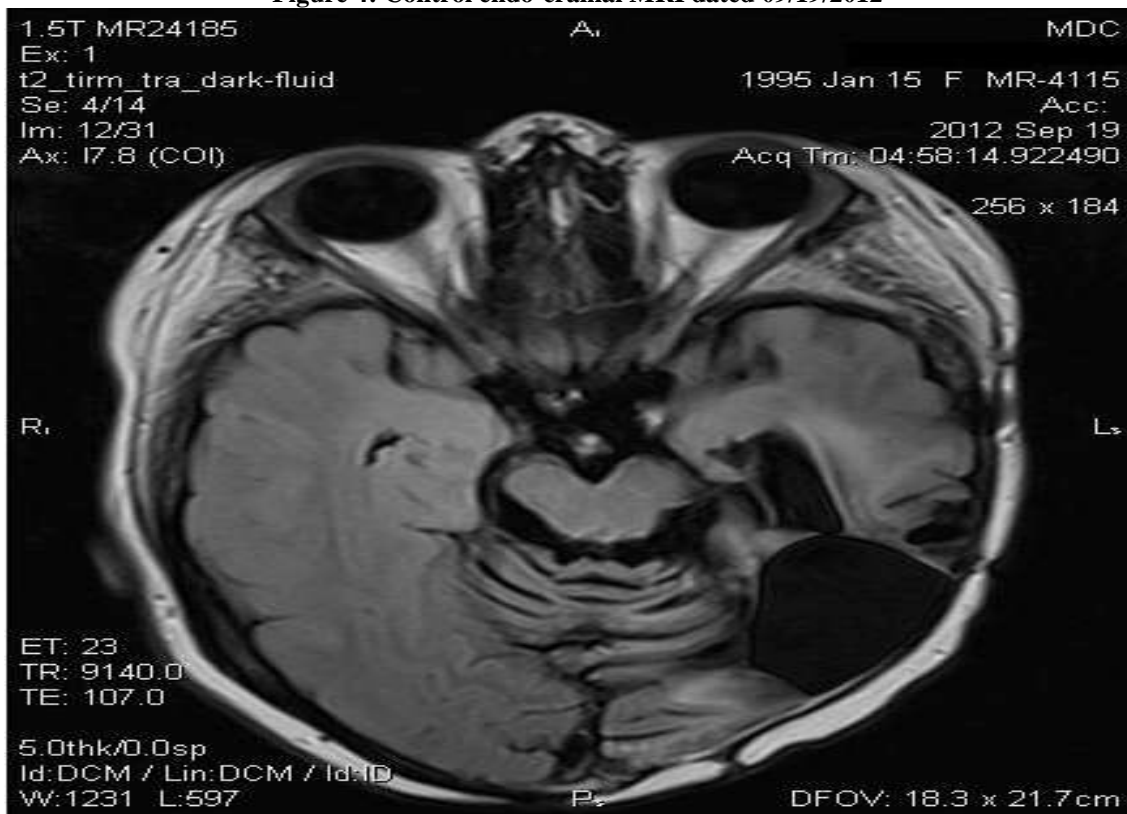
**Note:** In comparison to the previous MRI dated 09/20/2010, the lesion in question is reshaped; it used to be nodular, but currently appears to be more plate-like.

2. Sub-dural hygroma in the surgery zone.

3. Inflammatory changes of the left mastoid cells.”



Figure 4: Control endo-cranial MRI dated 09/19/2012



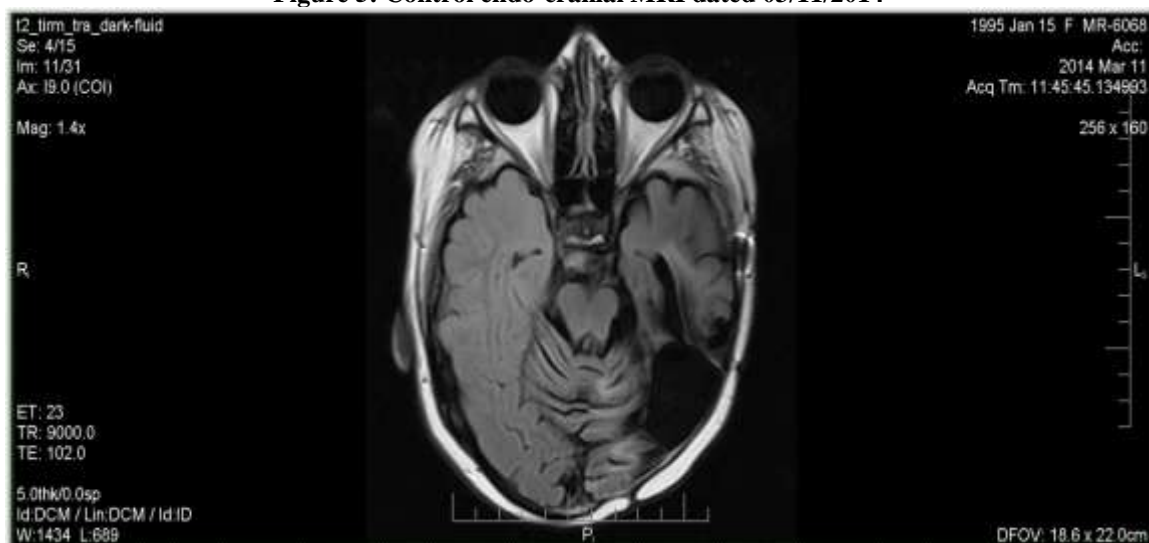
“State post left-sided osteoplastic craniotomy. In the temporal/parietal/occipital region, in specific in the area hosting the lateral and medial occipital/temporal gyri and hippocampus (whose body and tail had been partly resected), a zone following the CSF flow footsteps and measuring not more than 41x36x30 mm on this day (as compared to the earlier 44x38x30 mm) can be found.

As of today, the marginal T1W hyper-signalling area (2x7 mm; AP-II ) seen adjacent to the wall of the large cystic zone, failed to be seen.

**Resume:**

State post left-sided osteoplastic craniotomy. In the temporal/occipital/parietal region signs of postoperative malacia of the brain parenchyma can be witnessed, together with the signs of marginal postoperative and post-irradiation gliosis. Signs of recurrence of the primary condition are lacking. In the left frontal area, a discrete ischemia can be found. An excellent postoperative status with no signs of recurrence at all.”

Figure 5: Control endo-cranial MRI dated 03/11/2014



**“State post left-sided osteoplastic craniotomy.** In the temporal/parietal/occipital region, in specific in the area hosting the lateral and medial occipital/temporal gyri and hippocampus (whose body and tail had been partly resected), a zone following the CSF flow footsteps and measuring not more than 41x36x30 mm on this day (as compared to the earlier 41x36x30 mm) can be found.

**Resume:**

State post left-sided osteoplastic craniotomy. In the temporal/occipital/parietal region signs of postoperative malacia of the brain parenchyma can be witnessed, together with the signs of marginal postoperative and post-irradiation gliosis. Signs of recurrence of the primary condition are lacking. In the left frontal area, a discrete ischemia can be found.

**IMPROVEMENT WITNESSED THROUGHOUT THE PHYTOTHERAPY COURSE**

**Table 1: Tabulated display of phytotherapy outcomes**

| Control MRI dates | Tumour residuum dimensions      | Postoperative zone dimensions | Time elapsed from the PT launch ( months ) | Sings of recurrence |
|-------------------|---------------------------------|-------------------------------|--|---------------------|
| 09/20/2010        | 8x6 mm<br>( <b>Figure 2</b> )   | 59x36x33 mm                   | 5  | Lacking             |
| 12/23/2010        | 3x6x8 mm<br>( <b>Figure 3</b> ) | 53x41x31 mm                   | 8  | Lacking             |
| 05/17/2011        | 2x4x8 mm                        | 53x41x31 mm                   | 14   | Lacking             |
| 09/20/2011        | 2x7 mm                          | 50x36x29 mm                   | 18   | Lacking             |
| 03/09/2012        | 2x7 mm                          | 44x38x30 mm                   | 24   | Lacking             |
| 09/19/2012        | 0<br>( <b>Figure 4</b> )        | 41x36x30 mm                   | 30   | Lacking             |
| 02/25/2013        | 0                               | 41x36x30 mm                   | 35   | Lacking             |
| 09/18/2013        | 0                               | 41x36x30 mm                   | 42   | Lacking             |
| 03/11/2014        | 0<br>( <b>Figure 5</b> )        | 41x36x30 mm                   | 48   | Lacking             |

**Legend: PT=Phytotherapy**

### III. DISCUSSION

Despite enormous efforts engaged to the effect of improving the effectiveness of treatment administered to GBM patients and prolonging their life, and despite of hundreds of clinical trials striving to find a way to achieve the above goals, a substantial advancement in this regard failed to be seen. GBM still less than 9 months on the average; even after an aggressive therapy in terms of surgery, chemo-and radiotherapy, the disease tends to recur 6 to 12 months post treatment (Castro et al, 2003 ). Nevertheless, the length of survival seen across GBM patients can substantially vary; as of now, several prognostic factors capable of affecting the length of survival have been identified (Hulshof et al, 2001 ). Identification and recognition of such prognostic factors and the assessments of survival length made based on the latter, are of significance for the assessment of various treatments' effectiveness and the introduction of novel GBM-treating drugs.

#### Preoperative size of the tumour

Several studies have identified the preoperative size of the tumour to be an important independent predictor of the survival length. The study comprising a total of 510 malignant glioma patients, out of which 80% diagnosed with GBM, showed the tumour size to be an important prognostic indicator independent of other prognostic variables (Wood et al, 1988 ).

The importance of the preoperative tumour size was emphasised also by the study comprising a total of 63 astrocytoma patients, out of which 65%diagnosed with GBM, where the shortest average survival of 24 weeks was seen in the patient having a tumour measuring over 50 mm in average diameter (Kostić et al, 2007 ).

The study comprising a total of 76 patients diagnosed with high-grade astrocytomas, out of which 51 diagnosed with GBM, showed the survival length to be statistically significantly shorter in patients having the average tumour diameter of more than 50 mm ( Würschmidt et al 1995 ).

Based on the mathematical model that takes into account the tumour growth rate and the diffusion coefficient, it can be predicted that, on the average, GBM patients will not get to live longer than 158 days post diagnosis, as also foreseen by a number of trials ( Swanson et al, 2002 ). The average tumour diameter registered in our patient was 60 mm ( $D_{1-3max} = (a+b+c)/3$ ), putting her therefore into the poor prognosis patient group expected to live shorter.

### Radio/chemotherapy

GBM treatment starts with surgery that aims at alleviating or even annulling the adverse effects caused by the compression exerted by the tumour mass; due to such a tumour resection, the life of a GBM patient can be prolonged for 6 months tops (Shand et al, 1999).

In line with the standard oncologic protocol, surgery should be followed by a combination of radio-and (temozolomide) chemotherapy. Within the frame of radiotherapy, a total dose of 60Gy should be applied in 30 cycles, meaning that the patient receives 2 Gy a day ( Yaneva et al, 2010 ). Concurrent administration of temozolomide and radiotherapy has managed to further prolong the life of the diseased, but only of those having a more favourable preoperative Karnofsky index ( Hulshof et al, 2001 ).

Due temozolomide dose equals to 75mg/m<sup>2</sup> body surface/day and should be administered throughout the radiotherapy course. Following the completion of radiotherapy, a 18-day break should take place, followed by 150-200 mg/m<sup>2</sup> body surface/day temozolomide for the next five days; in total, 6 temozolomide cycles should be scheduled in 28-day intervals (Crott, 2007 ). Nevertheless, our patient was subjected to radiotherapy for 28 days only; the daily dose she received was as per protocol (2 Gy per day), but was still insufficient on the whole (a total of 56 Gy instead of 60 as due). As for temozolomide, due daily dose of 75mg/m<sup>2</sup> body surface had been applied, but for 28 days only, that is to say, only throughout the radiotherapy course. In response to this combined therapy, side-effects in terms of nausea and vomiting had been witnessed and treated with antiemetic drugs. Such a faulty treatment protocol had definitely diminished the chances for our patient's survival.

### Brain oedema

The intenseness and the extensiveness of brain oedema represent major prognostic factors that affect the length of recurrence-free interval and ultimately also the length of survival of GBM patients. One of the mechanisms responsible for GBM resistance to cyto-toxic drugs is exactly the brain oedema that exerts compression upon capillaries and leads to the formation of hypoxic zones in which the concentration of cytostatic drugs can be drastically reduced (Schoenegger et al, 2009 ). The second major consequence of brain oedema is the shifting of the tumour infiltration zone that goes in favour of tumour cell migration and enables these cells to penetrate into the parts of the brain hard to be either operated on or irradiated. Due to the aforementioned, the intenseness of the brain oedema is considered to be an exact mirror of the extensiveness of tumour cell infiltration. Due to shorter recurrence-free periods seen post surgery, GBM patients having a brain oedema of over 75cm<sup>3</sup>, have been shown to live statistically significantly shorter (Seidel et al, 2011 ). Given the aforementioned facts, it can definitely be concluded that the length of recurrence-free period should be taken as a key prognostic factor indicative of the length of survival of GBM patients.

As for our patient, MRI showed an extensive brain oedema occupying almost the entire left brain hemisphere, so that it was safe to assume that the recurrence shall appear soon; however, even after 48 months post diagnosing the recurrence failed to be seen. The study comprising a total of 206 GBM patients showed that even in patients having favourable prognostic factors, methylated promoter MGMT (O-6-methylguanine-DNA methyltransferase) included, and managed according to a flawless treatment protocol, the length of recurrence-free interval equalled to 10.3 months tops (Hegi et al, 2005 ).

Given the above-elaborated unfavourable prognostic factors on one hand, and the fact that in our patient the disease failed to progress even four years post diagnosing on the other, we have grounds to believe that phytotherapy deserves a credit for an amazing prolongation of life of our GBM patient. At the time of submission of this article, our patient attended school on a regular basis and did not experience any symptoms suggestive of GBM recurrence whatsoever.

## IV. CONCLUSION

Given the preoperative size of the tumour, large areas of haemorrhagic necrosis, brain oedema encompassing virtually the entire left brain hemisphere, faulty oncologic treatment and poor overall health seen in our patient prior to phytotherapy launch, we have grounds to believe that phytotherapy made a substantial



contribution to the tumour residuum regression and deserves credit for a long recurrence-free survival witnessed in our patient.

## V. FINANCING

This investigation was financed by the Family Business "DREN" Ltd, Žepče, Bosnia and Herzegovina, whose founders are sole designers of the herbal mixtures used to treat our GBM patient and hold the exclusive rights to distribute and sell the preparations in reference.

## ACKNOWLEDGEMENT

We are profoundly grateful to our young patient for her regular and long-term use of our herbal remedies, as well as to her family for putting trust in us and the possibility to treat such an ominous disease using phytotherapeutic preparations.

## REFERENCES

- [1]. Burger, P.C., Scheithauer, B.W. ( 2007 ). Tumors of the Central Nervous System. AFIP Atlas of Tumor Pathology.
- [2]. Castro, M.G., Cowen, R., Williamson, I.K., David, A., Jimenez, Dalmaroni, M.J., Yuan, X., Bigliari, A., Williams, J.C., Hu, J., Lowenstein, P.R. ( 2003 ). Current and future strategies for the treatment of malignant brain tumors. *Pharmacol Ther.* , 98: 71 – 108.
- [3]. Crott, R. ( 2007 ). The economics of temozolomide in brain cancer, *Expert Opin Pharmacother.* , Aug 8 (12):1923-9.
- [4]. Hegi, M.E., Diserens, A.C., Gorlia, T., Hamou, M.F., Tribolet, N., Weller, M., Kros, J.M., Hainfellner, J.A., Mason, W., Mariani, L., Bromberg, J.E.C., Hau, P., Mirimanoff, R.O., Cairncross, J.G., Janzer, R.C., and Stupp, R. ( 2005 ). MGMT Gene Silencing and Benefit from Temozolomide in Glioblastoma. *N Engl J Med.* , March 10; 352:997-1003.
- [5]. Hulshof, M.C., Koot, R.W., Schimmel, E.C. et al ( 2001 ). Prognostic factors in glioblastoma multiforme. 10 years experience of a single institution. *Strahlenther Onkol.* , Jun;177(6):283-90.
- [6]. Kostić A, Babić M, and Jančićjević M. ( 2007 ). Survival of Brain Astrocytoma Patients Considering Preoperative Tumor. *Acta Medica Medianae.* 46(1):17-20.
- [7]. Louis, D.N., Ohgaki, H., Wiestler, O.D. et al ( 2007 ). The 2007 WHO Classification of Tumours of the Central Nervous System, *Acta Neuropathol.* , August; 114(2): 97–109.
- [8]. Lukić, P.B. (1993). *Pharmacognostics.* Faculty of Pharmacy University of Belgrade: 18 – 24.
- [9]. Ohgaki, H., Dessen, P., Jourde, B., Horstmann, S., Nishikawa, T., Di Patre, P.L., Burkhard, C., Schuler, D., Probst-Hensch N.M., Maiorka, P. et al ( 2004 ). Genetic pathways to glioblastoma: a population-based study, *Cancer Res* 62:6892-9.
- [10]. Ohgaki, H., Kleihues, P. ( 2005 ). Population – based studies on incidence, survival rate, and genetic alterations in astrocytic and oligodendroglial gliomas. *J Neuropathol Exp Neurol.* , 64:479-89.
- [11]. Ohgaki, H., Watanabe, K., Peraud, A., Biernat, W., von Deimling, A., Yasargil, M.G. et al ( 2009 ). A case history of glioma progression. *Acta Neuropathol.* , 87:525-32.
- [12]. Schoenegger, K., Oberndorfer, S., Wuschitz, B., Stuhel, W., Hainfellner, J., Prayer, D. et al. ( 2009 ). Peritumoral edema on MRI at initial diagnosis: an independent prognostic factor for glioblastoma?. *Eur J Neurol.* , 16(7):874-8.
- [13]. Seidel, C., Dörner, N., Osvald, M., Wick, A., Platten, M., Bendsuz, M. et al. ( 2011 ). Does age matter? – A MRI study on peritumoral edema in newly diagnosed primary glioblastoma. *BMC Cancer.* Apr 12 ;11( 1 ):127-31.
- [14]. Shand, N., Weber, F., Mariani, L., Bernstein, M., Gianella-Borradori A., Long, Z., Sorensen, A.G., Barbier, N. ( 1999 ). A phase 1-2 clinical trial of gene therapy for recurrent glioblastoma multiforme by tumor transduction with the herpes simplex thymidine kinase gene followed by ganciclovir. *GLI 328 European Canadian Study Group Hum Gene Ther.* , 20;10 (14):2325-35.
- [15]. Stupp, R., Mason, W.P., van den Bent, M.J. ( 2005 ). European Organisation for Reserch and Treatment of Cancer Brain Tumor and Radiotherapy Groups, National Cancer Institute of Canadian Clinical Trials Group. Radiotherapy plus concomitant and adjuvant temozolomide for glioblastoma. *N Engl J Med.* , 352:987-996.
- [16]. Swanson, K.R., Alvord, Jr EC., Murrau, J.D. ( 2002 ). Virtual brain tumours (gliomas) enhance the reality of medical imaging and highlight inadequacies of current therapy. *British Journal of Cancer.* 86; 14-8.
- [17]. Trogrlić, I., Trogrlić, D., and Trogrlić, Z. ( 2012 ). The influence of phytotherapy on Macroprolactinoma Size. *AJTCAM* 9 (2): 277-286.
- [18]. Trogrlić, I., Trogrlić, D., and Trogrlić, Z. ( 2012 ). The influence of phytotherapy on prolactin level in macroprolactinoma patients. *AJTCAM* 9 (1): 67-72.
- [19]. Van Meir, E.G., Hadjipanayis, C.G., Norden, A.D., Shu, H-K., Wen, P.Y., Olson, J.J. ( 2010 ). Exciting new advances in neuro-oncology: the avenue to a cure for malignant glioma. *CA Cancer J Clin.* , 60:166-93.
- [20]. Wood, J.R., Green, S.B., Shapiro, W.R. ( 1988 ). The prognostic importance of tumor size in malignant gliomas: a computed tomographic scan study by the Brain Tumor Cooperative Group. *J Clin Oncol.* , 6(2):338-43.
- [21]. Würschmidt, F., Bünemann H., Heilmann H.P., ( 1995 ). Prognostic factors in high-grade malignant glioma. A multivariate analysis of 76 cases with postoperative radiotherapy. *Strahlenther Onkol.* , 171(6):315-21.
- [22]. Yaneva, M.P., Semerdjieva, M.L., Radev, L.R., Vlaikova, M.I. ( 2010 ). Postoperative chemo-radiotherapy with temodal in patients with glioblastoma multiforme--survival rates and prognostic factors. *Folia Med (Plovdiv).* 01; 52(1):26-33.